

## ORIGINAL ARTICLE

# FUNCTIONAL DISORDERS OF THE SALIVARY GLANDS IN PATIENTS WITH COMPRESSION AND DISLOCATION DYSFUNCTION OF THE TEMPOROMANDIBULAR JOINT AND THEIR CORRECTION

DOI: 10.36740/WLek202107124

**Oleg V. Rybalov**, Pavel I. Yatsenko, Olga Yu. Andriyanova, Elena S. Ivanytska, Maria A. Korostashova

POLTAVA STATE MEDICAL UNIVERSITY, POLTAVA, UKRAINE

## ABSTRACT

**The aim:** Is to assess the functional state of parotid glands and general secretion in patients with compression, dislocation dysfunction of TMJ, to correct the revealed disorders.

**Materials and methods:** We examined 46 patients with dysfunction of TMJ. Examination included TMJ zonography and salivary glands sonography. We studied the general and parotid secretion, transparency, viscosity, pH of the oral fluid and the secretions of the parotid glands before and after treatment. The treatment of dysfunction and hyposalivation included the repositioning of the articular heads of the lower jaw in the correct anatomical position, the use of a repositioning plate on the posterior teeth at the compression side of the articular head, bougienage of the duct of the parotid gland, administration of 10% magnesium-mineral solution of bischofite into the gland.

**Results:** In patients with TMJ dysfunction, a significant decrease in the oral fluid content was noted before treatment. The saliva transparency was reduced, the viscosity was increased, the pH was slightly acidic. A study, which was carried out a month after completion of the course of treatment showed that all the studied parameters corresponded to those in healthy individuals.

**Conclusions:** The study confirmed that in compression and dislocation dysfunction of TMJ, there are disorders of the functional state of the salivary glands.

**KEY WORDS:** TMJ, dysfunction, parotid gland, secretion, treatment

Wiad Lek. 2021;74(7):1695-1698

## INTRODUCTION

In the scientific literature, which relates to the pathology of the temporomandibular joint (TMJ), there are references to functional disorders of the salivary glands in Costen-syndrome [1, 2] and in dysfunctional conditions of TMJ [3]. This is explained by the fact that salivary glands are the peripheral departments of those executive functional systems that are closely related to the external environment, and they are the first to respond to any changes in it [4, 5]. The effect of the mutual influence of dysfunctional conditions of TMJ and secretion of the salivary glands, especially the parotid, located in the zone of articular pain, the zone of the autonomic innervation network, is fully justified [6]. In patients with TMJ, during endoscopy of the ducts of the parotid salivary glands, it was found that there is a pronounced edema in their glandular duct system, lacunar enlargement and stenosis, the color of the walls of the ducts from whitish-yellow to burgundy with areas of ischemia. These changes were accompanied by functional disorders of the salivary glands and were more pronounced in severe disorders of TMJ [7]. The authors concluded that the revealed reactive abnormalities in the parotid salivary glands with varying severity of TMJ dysfunction have an important diagnostic value [8].

In publications devoted to the issues of sialogy, there are numerous descriptions of the symptomatic treatment

of dysfunction of the salivary glands in the form of hyposalivation. In particular, it is recommended to treat the mucous membranes of the oral cavity with Hyposalix spray, Bensinol artificial saliva, potassium iodide solutions, pilocarpine, galantamine, vitamin A concentrate, novocaine blockages of the regions of the parotid and submaxillary glands and physiotherapeutic procedures: galvano therapy of salivary glands, electrophoresis with potassium iodide or galantamine, and vibration massage are prescribed [9,10].

However, in the presence of a significant number of publications in the sections of TMJ pathologies, until now there are no clear ideas on methods for correcting disorders of the secretory function of the salivary glands, in particular the parotid, with dysfunctional TMJ conditions [11, 12, 13].

## THE AIM

The aim of the research was to assess the functional state of the parotid salivary glands and general secretion in patients with compression and dislocation dysfunction of TMJ and to correct the revealed disruptions.

## MATERIALS AND METHODS

We examined 46 patients with compression and dislocation dysfunction of TMJ with the disease duration (from

the moment of the first signs) from 1.5 years to 3.5 years. The age of patients ranged from 23 to 45 years. The study included 7 men and 39 women. When assessing complaints of patients, we paid attention to the time of onset of symptoms of TMJ dysfunction and the feeling of dryness in the oral cavity. The condition of the red border of the lips, the corners of the mouth, the mucous membrane of the oral cavity, and the degree of its moisture were evaluated. According to generally accepted methods, without stimulation of secretion, general sialometry was performed; the secretory function of the parotid glands was studied by draining the main ducts with metal catheters. The secretion was collected in volumetric tubes for 10 minutes [14]. The physicochemical properties of the oral fluid and the secretions of the parotid glands (pH, viscosity, transparency) were studied. The control group consisted of 9 women aged 28-39 who did not suffer from neurological diseases and did not have any TMJ and salivary gland pathologies. In all examined patients, the state of TMJ components was evaluated according to their zonography with the patient's mouth closed and open. Ultrasound examination of the parotid salivary glands was conducted in 17 patients.

The protocol of therapeutic measures in patients with TMJ compression and dislocation dysfunction included repositioning of the articular heads of the lower jaw to the correct its anatomical position, using a repositioning plate on the chewing teeth on the compression side of the articular head [15], bougienage of the duct of the parotid gland on this side, administering 10% magnesium-mineral solution of bischofite into the gland, with activation of the secretory process of the digestive glands [16]. This procedure (5 instillations) was carried out 2 times a week. After a seven-day break, the course of treatment ended with a five-time injection of rosehip oil into the gland.

## RESULTS

The diagnosis of compression and dislocation dysfunction of TMJ was made on the basis of patients complaints of pain in the area of one of the joints, hearing impairment and tinnitus in the ear on this side, extraneous sounds in the symmetric joint in the form of crunching, rustling, clicking, inadequate displacement of the lower jaw towards the joint with pain symptom, dry mouth.

On examination, dry red border of lips with vertical fissures was observed in 28 patients. The oral mucosa was moistened, but there was no free oral fluid. From the duct of the parotid gland on the side of the pain symptom, a small amount of secretion was released. The secretion from the symmetric gland was moderate.

On palpation, the area of the problem TMJ was painful. Patients noted severe pain in the upper pole of the parotid gland and in the middle region of the masticatory muscle at the level of the main duct of the gland on the side of the joint with pain symptom.

On the TMJ zonograms with the patient's mouth closed, a significant decrease in the articular cavity on the side of the joint with pain symptom (compression phenomena), characteristic

for compression and dislocation dysfunction, and its expansion in the symmetric joint, was noted. With the open mouth, the articular head of this joint went beyond the top of the articular tubercle anteriorly (dislocation of the articular head). In the joint with compression phenomena, it did not reach the top of the tubercle and was located on its posterior slope (Fig. 1).

Ultrasound examination of the salivary glands revealed that on the side of TMJ with the phenomena of compression symptom, there was a slight increase in the parotid glands, densification of their capsules, uniform structure in places with alternating sections of different echogenicity due to small inclusions and narrowing of the ducts. Vascularization of the glands was not enhanced in all 17 patients; in 6 of them, lymph nodes from 6 mm to 9 mm in size were found in the glands (Fig. 2).

According to the results of general sialometry in patients with compression and dislocation dysfunction, a significant ( $P < 0.05$ ) decrease in the content of oral fluid was noted before treatment and it was  $2.94 \pm 0.31$  ml per 10 minutes of the study (in healthy subjects –  $4.23 \pm 0.09$  ml). The saliva transparency was reduced to  $0.032 \pm 0.005$  cu, the viscosity of the oral fluid increased up to  $1.12 \pm 0.05$  cPs (in healthy  $1.01 \pm 0.01$  cPs), its pH had a slightly acidic reaction and amounted to  $7.22 \pm 0.05$  (healthy –  $7.39 \pm 0.07$ ).

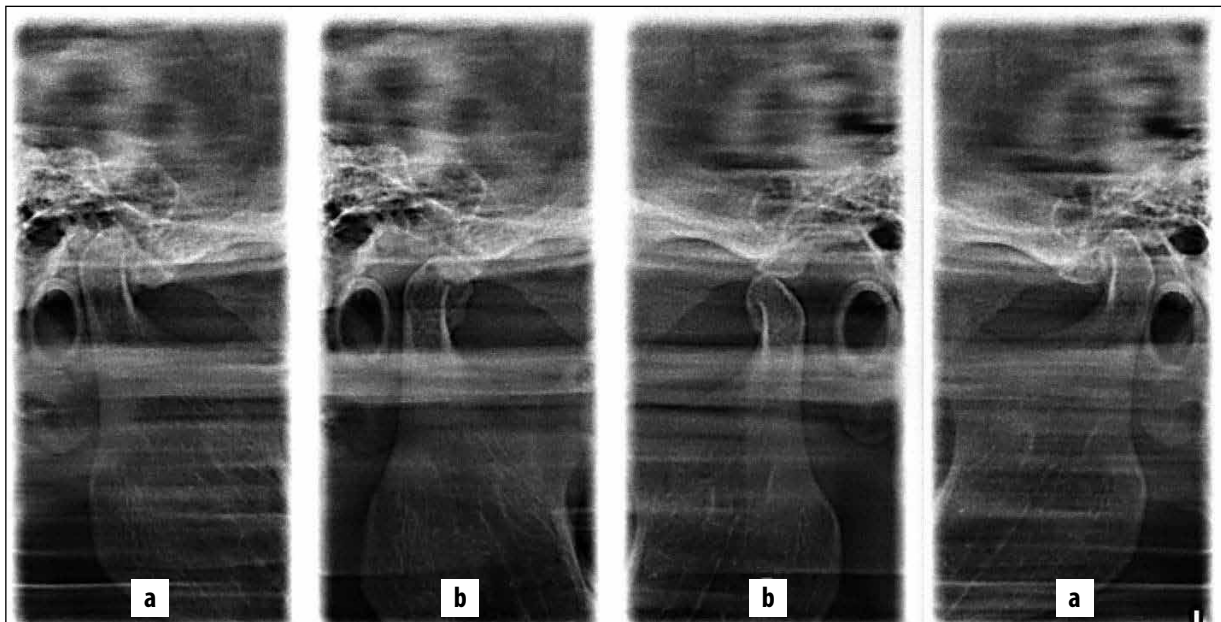
The secretion of the parotid glands on the side of the pain compression symptom was within  $1.6 \pm 0.14$  ml per 10 minutes of the study (in healthy patients,  $2.04 \pm 0.61$  ml) –  $P < 0.05$ . A decrease in the transparency of the secretion was noted up to  $0.027 \pm 0.005$  cu (in healthy ones –  $0.021 \pm 0.002$  cu), an increase in the viscosity of the parotid secretion up to  $2.68 \pm 0.05$  cPs (in healthy subjects –  $2.59 \pm 0.04$  cPs). The pH of the secretion of the parotid glands had a weakly acid reaction –  $7.08 \pm 0.09$  (in healthy  $7.49 \pm 0.07$ ),

The secretion of the parotid glands on the side of dislocation of the articular head corresponded to secretion in healthy individuals and amounted to  $2.01 \pm 0.39$  ml. Indicators of viscosity, transparency and pH also did not differ from those in healthy individuals.

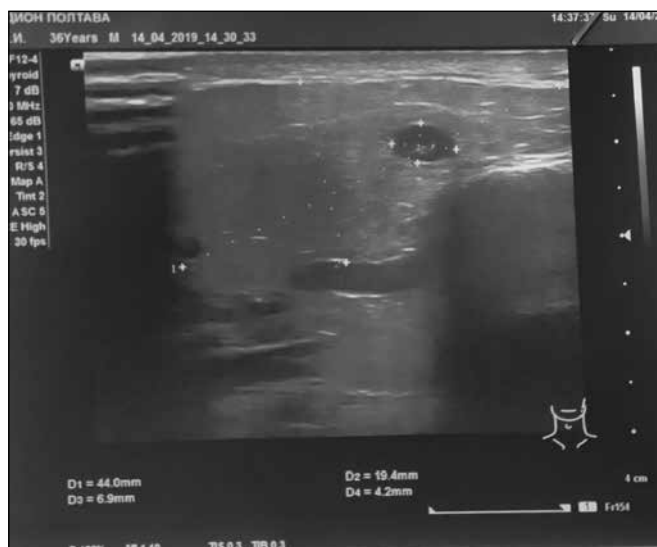Examination of patients a month after completing the course of treatment revealed the absence of symptoms of TMJ dysfunction, there were no complaints of dry mouth. A study in the dynamics of observation of total secretion showed that in 10 minutes  $4.30 \pm 0.11$  ml of oral fluid was secreted by the salivary glands, which corresponded to salivation in healthy individuals.

The secretion of the parotid glands on the side of the former pain compression symptom approached the value of secretion in healthy people:  $1.9 \pm 0.21$  ml per 10 minutes of the study ( $P > 0.05$ ). The secretion transparency was restored ( $0.022 \pm 0.003$  cu), the viscosity of the parotid secretion was  $2.61 \pm 0.05$  cPs ( $P > 0.05$ ). The pH of the secretion of the parotid glands was slightly different from that in healthy individuals –  $7.43 \pm 0.05$  ( $P > 0.05$ ).

Thus, our study confirmed that in patients with compression and dislocation dysfunction of TMJ, there are disruptions of the functional state of the salivary glands: a decrease in total and parotid secretion, a change in the viscosity of the oral fluid and secretion of the parotid glands, their transparency, pH.



**Fig. 1.** TMJ zonography (29-year-old patient N.) with closed (a) and with open mouth (b). There is a narrowing of the articular gap of the right joint with a closed mouth (compression) and a dislocation of the left articular head with an open mouth anteriorly to the apex of the articular tubercle to its anterior slope. Diagnosis: compression-dislocation dysfunction of temporomandibular joint.



**Fig. 2.** Sonogram of the left parotid salivary gland (36-year-old patient B.) The main diagnosis: compression-dislocation dysfunction of temporomandibular joint: compression on the left, dislocation of the articular head on the right. Capsule densification is noted in some places. Areas of different echogenicity due to small inclusions, narrowing of large ducts are visualized on the background of a homogeneous structure. Vascularization of the gland is not enhanced. There is the lymph node (6.9 mm x 4.7 mm in size) in the thickness of the gland. Ultrasound signs of mild interstitial sialadenitis.

Ultrasound examination of the parotid glands on the side of the joint with manifestations of compression pain symptom revealed the initial signs of interstitial inflammation. Adjusting the articular heads in the correct anatomical position, therapeutic exercises for the musculo-articular complex, the use of a repositioning rubber plate on the chewing teeth

on the compression side of the joint head, bougienage of the duct of the parotid gland on this side, injection of 10% magnesium-mineral solution of bischofite and rosehip oil into the gland leads to the elimination of the phenomena of TMJ dysfunction and dry mouth, as well as normalization of secretion by the salivary glands.

## DISCUSSION

In the presence of an articular compression pain symptom, in the pathogenesis of the salivary glands dysfunction, in particular the parotid glands, it is most likely that the leading aspect in this process is a disruption of the peripheral mechanisms and humoral structures of the sympathetic and autonomic nervous system [17]. This is due to the common vegetative innervation of the salivary glands, mucous membranes of the oral cavity, nose, paranasal sinuses and components of the temporomandibular joint [18]. When conducting therapeutic measures in patients with TMJ dysfunctional conditions, the main attention of doctors is given to eliminating the pain symptom, whereas the therapeutic actions for the impaired functions of the salivary glands are not carried out. The described treatment complex for eliminating the phenomena of dry oral cavity can be used not only in patients with compression and dislocation dysfunction of TMJ, but also in other diseases accompanied by a decrease in the functional activity of the salivary glands.

## CONCLUSIONS

The study confirmed that in compression and dislocation dysfunction of TMJ, there are disorders of the functional state of the salivary glands.

## REFERENCES

- Gajvoronskij I.V., Vojtjackaja I.V., Iordanishvili A.K. et al. Anatomicheskie predposylki sindroma Kostena [Anatomical background of Kosten syndrome]. Kurskij nauchno-prakticheskij vestnik "Chelovek i ego zdorov'e".2014;1:24–28. (In Russian).
- Fachira A. Procedure for the diagnosis of temporomandibular joint dysfunctions *Medicina Stomatologică*. 2017;4(45):20–26.
- Makeev V.F., Telishevs'ka U.D., Shibins'kij V.J.A. et al. Skronevo-nizhn'oshhelepni rozladi [Temporomandibular disorders] *L'viv: Kvart*; 2018, 400 p. (In Ukrainian).
- Podvjaznikov S.O. Kratkij vzgljad na problemi kserostomii opuholi golovy I shei [A brief look at the problem of xerostomia].2015;1:42 – 44. (In Russian).
- Ribalov O.V., Buhanchenko O.P., Ivanic'ka O.S. Funkcional'ni reakcii slinnih zalozu hvorih pered planovimi rekonstruktivno-vidnovljuchimi operacijami [Functional reactions of salivary glands in patients before planned reconstructive surgery] *Materiali Vseukraïns'koï naukovopraktichnoï konferencii z miznarodnoju uchastju "Aktual'ni problem stomatologii, shhelepno-licevoi hirurgii, plastichnoï ta rekonstruktivnoï hirurgii golovi ta shii"*. – Poltava, 2014, 56 – 57p. (In Ukrainian).
- Egorov P.M., Karapetjan I.S. Bolevaja disfunkcija visochno-nizhnecheljustnogo sustava [Pain dysfunction of the temporomandibular joint] *Moskva: Medicina*; 1986,130 p. (In Russian).
- Korotkih N.G., Morozov A.N., Kelejnikova V.A. et al. Harakteristika morfofunktional'nyh narushenij okoloushnoj sljunnoj zhelezy pri disfunkcii visochno-nizhnecheljustnogo sustava [Characterization of morphofunctional disorders of the parotid salivary gland in temporomandibular joint dysfunction] *Rossijskij stomatologicheskij zhurnal*. 2013; 6:28 – 30. (In Russian).
- Strychowsky J.E., Sommer D.D., Gupta M.K., et al. Sialendoscopy for the management of obstructive salivary gland disease: a systematic review and meta-analysis. *Arch. Otolaryngol.-Head Neck Surg*. 2012; 138(6): 541–547.
- Afanas'ev V.V. Sljunnye zhelezy. Bolezni I travmy [Salivary glands. Diseases and injuries].*Moskva: Gjeotar-Media*; 2012, 296 p. (In Russian).
- Kapirulina O.V., Melehov S.V. Sravnitel'naja harakteristika tradicionnyh I sovremennyh metodov lechenija kserostomii po dannym literatury [Comparative characteristics of traditional and modern treatment methods of xerostomia overview] <http://www.grippa-net.net/bolezni/bolezni-zubov-i-polosti-rta/kserostomiya>.
- Yadav S.A. Study on Prevalence of dental attrition and its relation to factors of age, gender and to the signs of TMJ dysfunction. *J Indian Prosthodont*. 2011;11: 98 – 105.
- Zashhihin E.N., Oreshaka O.V, Mart'janova L.I Ocenka effektivnosti ortopedicheskogo lechenija pacientov pri syndrome zhzhenija jazyka, obuslovlennom disfunkciej visochno-nizhnecheljustnogo sustava [Evaluation of the effectiveness of orthopedic treatment of patients with tongue burning syndrome due to dysfunction of the temporomandibular joint]. *Rossijskij stomatologicheskij zhurnal*. 2012; 2:32–35. (In Russian).
- Jonathon R., Kirsch D.O. Associate an Osteopathic Manipulative Approach to Temporomandibular Joint Dysfunction Associate Physician Neuromusculoskeletal Medicine:OMM Marshfield Clinic Stevens Point Center Stevens Point, Wisconsin. – Presenting at WAOPSF all Seminar. 2015:34 – 38.
- Romacheva I.F., Judin L.A., Afanas'ev V.V. et al. Zabolevanija I povrezhdenija sljunnyh zhelez. [Diseases and injuries of the salivary glands] *Moskva: Medicina*; 1987, 240 p. (In Russian).
- Ribalov O.V., Novikov V.M., Yacenko P.I. et al. Patent na korisnu model' № 126149 «Pristrij dlja likuvannja kompresijnogo bol'ovogo simptomu pri dislokacijno-kompresijnij disfunkcii skronevo-nizhn'oshhelepno suglobu» [Device for the treatment of compression pain symptom in dislocation-compression dysfunction of the temporomandibular joint] *Zareestrovano 11.06 2018 r., Data publikacii 1 1.06.2018 Bul. № 11.* (In Ukrainian).
- Sysuev B. B. Tehnologicheskie I farmakologicheskie issledovanija minerala bishofit kak istochnika magnijsoderzhashhih lekarstvennyh sredstv [Technological and pharmacological studies of the bischofite mineral as a source of magnesium-containing drugs]: *dis. dokt. farm. nauk: 14.04.01 «farmakologija»*. Pjatigorsk; 2012, 409 p. <https://www.dissercat.com/content/tehnologicheskie-i-farmakologicheskie-issledovaniya-minerala-bishofit-kak-istochnika-magnii>.
- Segal K., Lisnyansky I., Nageris B. et al. Parasympathetic innervation of the salivary glands. *Operative Techniq. Otolaryngol-HeadNeck Surg*. 1996;7(4): 333–338.
- Grishkov M. S. Stomato-nevrologicheskie paralleli v diagnostike I lechenii miofascial'noj bolevoi disfunkcii lica: [Dental and neurological parallels in the diagnosis and treatment of myofascial painful face dysfunction] *dis. Kand. med.nauk:14.01.14«stomatologija»*:Moskva; 2010,135p. <https://www.dissercat.com/content/stomato-nevrologicheskie-paralleli-v-diagnostike-i-lechenii-miofascialnoi-bolevoi-disfunkts>.

*This study was conducted within the framework of self-financed research project of Poltava State Medical University "Application of modern technologies of diagnostics and treatment for rehabilitation of dental patients with orthopedic methods" (state registration number 0117U004778).*

**ORCID and contributionship:**

*Pavel I. Yatsenko*: 0000-0002-8440-8905 <sup>A,D</sup>

*Oleg V. Rybalov*: 0000-0001-9467-2913 <sup>A,F</sup>

*Olga Yu. Andriyanova*: 0000-0003-0864-7071 <sup>E</sup>

*Elena S. Ivanytska*: 0000-0002-4789-8503 <sup>D</sup>

*Maria S. Korostashova*: 0000-0002-0520-557X <sup>B,C</sup>

**Conflict of interest:**

*The Authors declare no conflict of interest.*

**CORRESPONDING AUTHOR**

**Pavel I. Yatsenko**

Poltava State Medical University

32 Shevchenko st., 36000 Poltava, Ukraine

tel: +380506338650

e-mail: 7610r777@gmail.com

**Received:** 2020-06-01

**Accepted:** 2021-06-01

**A** – Work concept and design, **B** – Data collection and analysis, **C** – Responsibility for statistical analysis, **D** – Writing the article, **E** – Critical review, **F** – Final approval of the article